Daniele Grassi
www.urologia-agopuntura.it

Urologia Funzionale
Urologia Femminile
Medicina Cinese e Agopuntura
Aromaterapia clinica, Fitoterapia

Il ruolo del biofilm nelle infezioni genito-urinarie: il punto di vista del ginecologo e dell'urologo

fppt.com

CISTITI RICORRENTI BATTERICHE
RUTI's: *Recurrent Urinary Tract Infections*

Definition

3> episodes of cystitis in the last 12 months
2> episodes in the last 6 months

Prevalence

1 out of 3 adult women experiences a cystitis
1 out of 4 of these will develop R-UTI's

ICS

fppt.com

Urinocoltura e antibiogramma

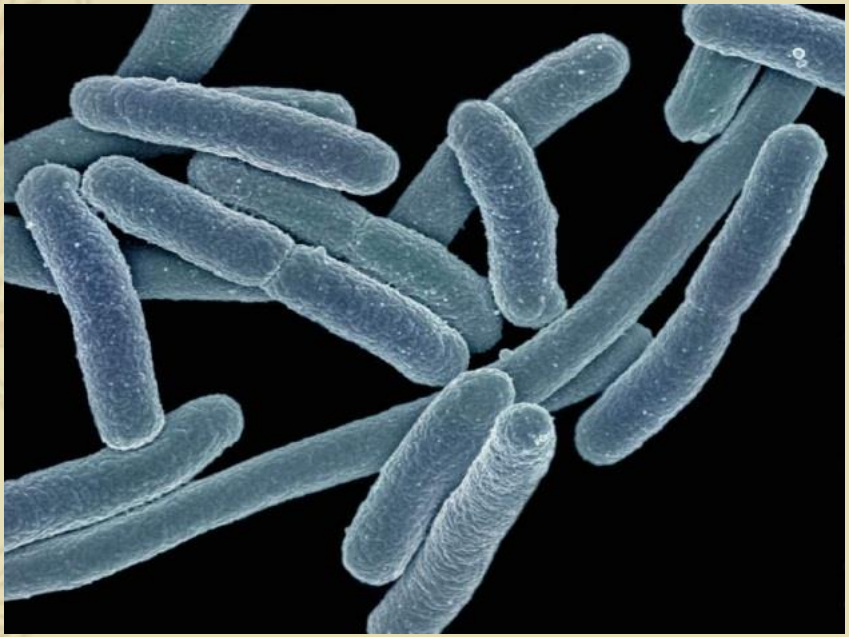

fppt.com

pH urinario



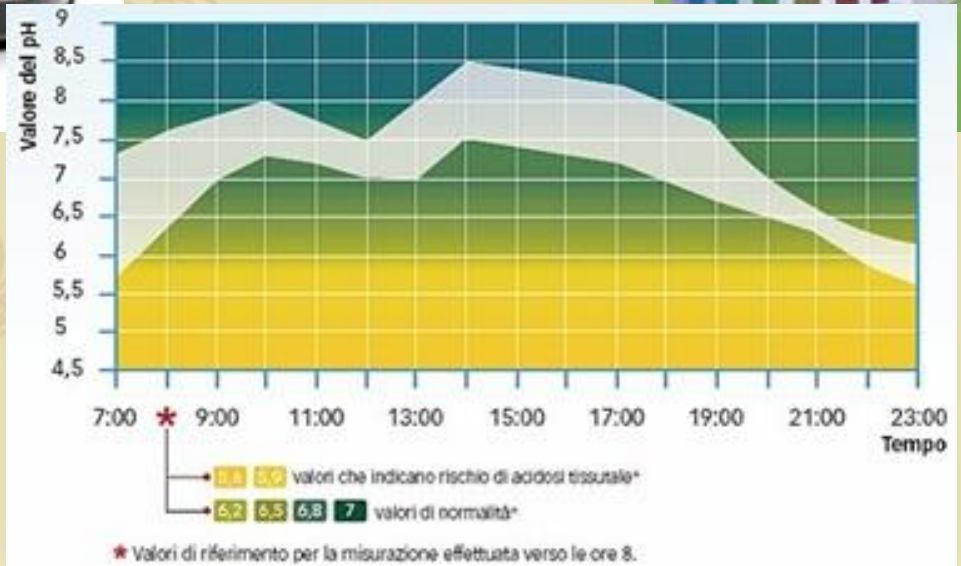

fppt.com

Recurrent Urinary Tract Infections
R-UTI's Species

85% ***Escherichia Coli***

15% ***Proteus Mirabilis, Enterococcus Fecalis***

KES (Urea-splitting bacteria): ***Klebsiella, Enterobacter, Serratia, Pseudomonas Aeruginosa, Staphylococcus Saprophyticus, Staphylococcus Aureus, Chlamydia Trachomatis, Mycoplasma, Candida Spp***

fppt.com

UPEC: Uropathogenic *Escherichia Coli* Virulence Factors

Type 1 pili: FimH adhesin molecule binds mannose-containing glycoprotein receptors of urothelial cells

Type 2 pili: secretion systems (T2SS) binds galactose-containing receptors

fppt.com

Antibioticoresistenza di E. coli - emo ed urinocolture (Regione Emilia-Romagna, 2003-2008)

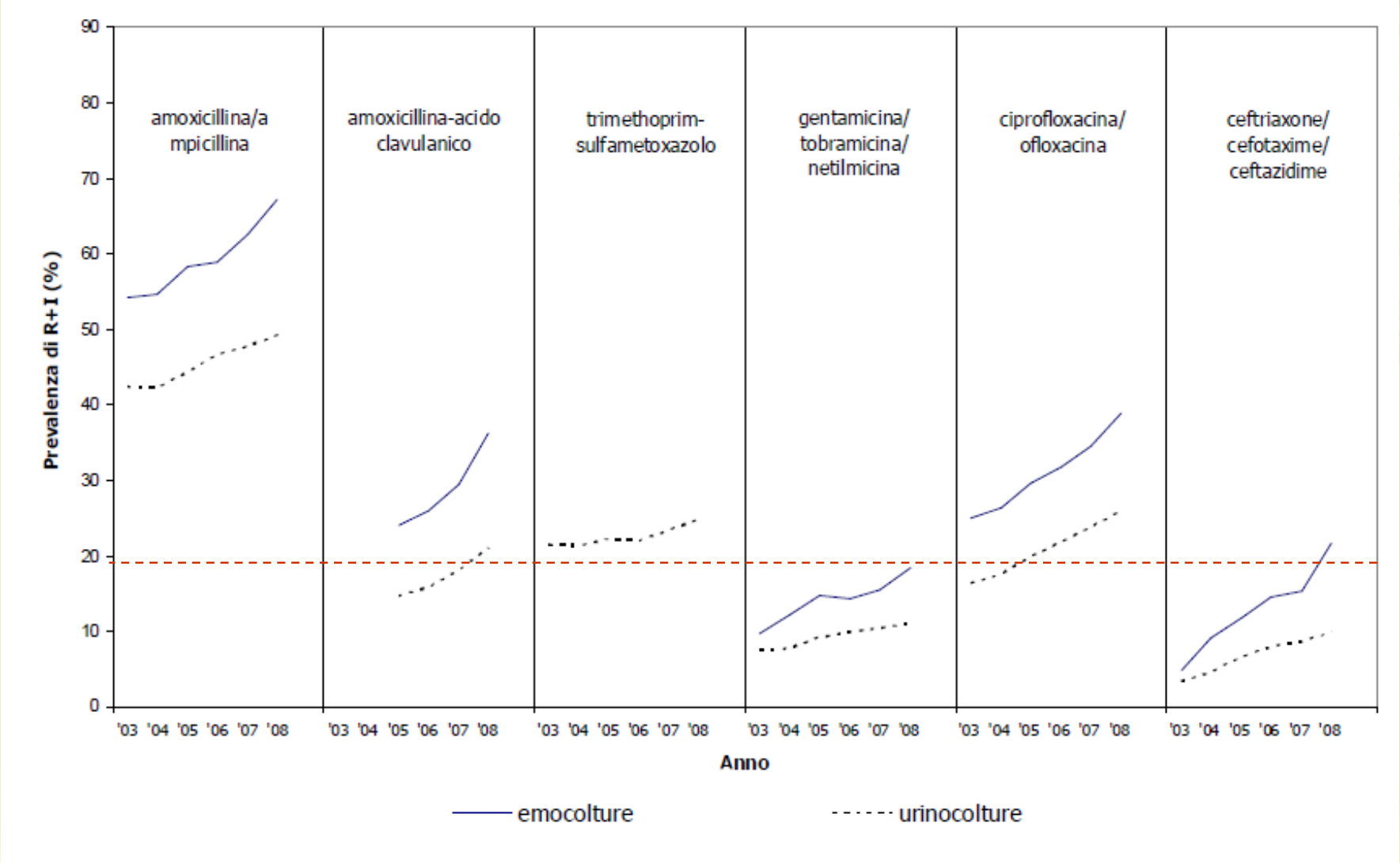

fppt.com

BIOFILM BATTERICI EXTRACELLULARI

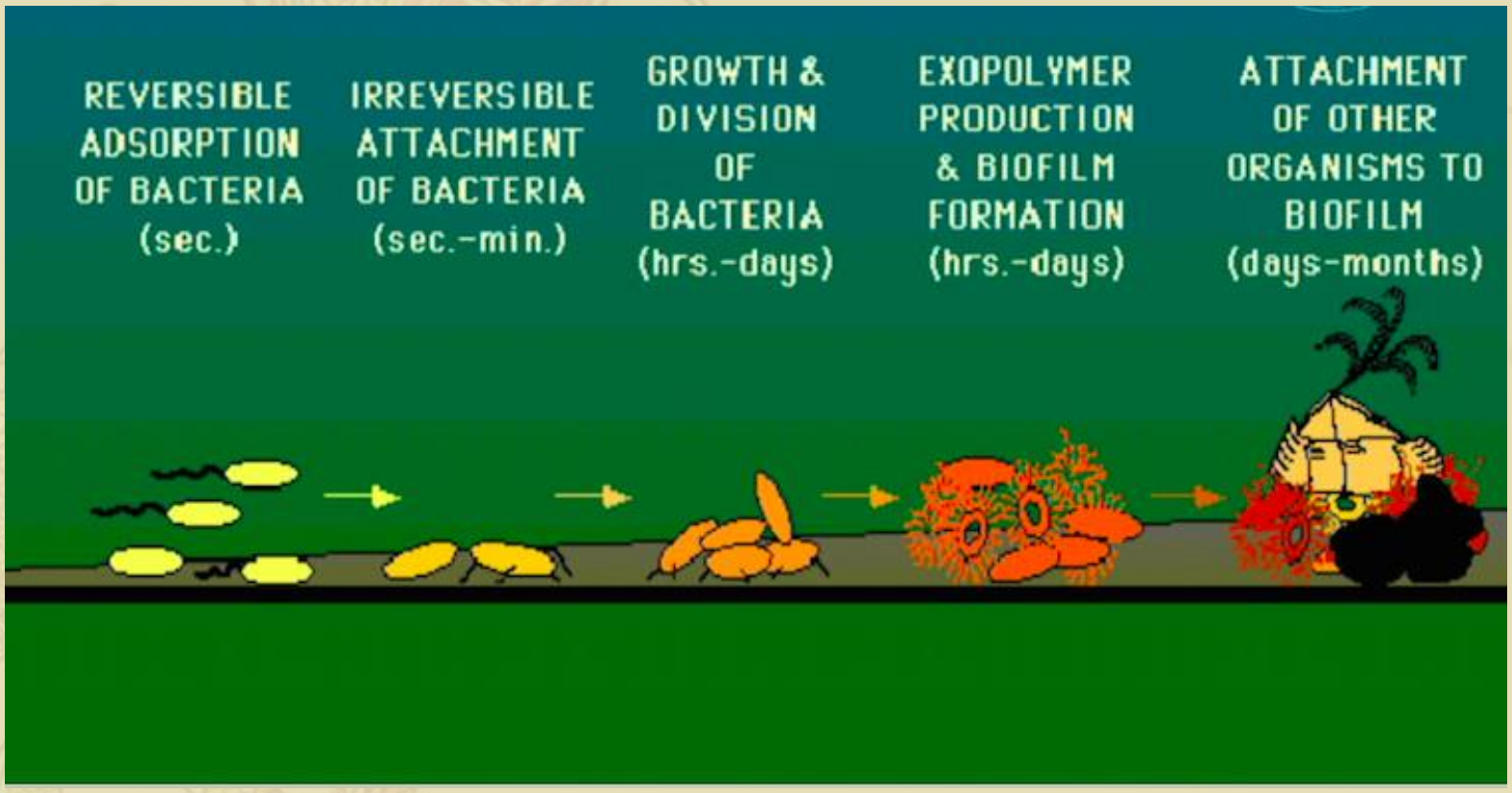

Comunità strutturate di cellule batteriche (con la compresenza di funghi) racchiuse in una matrice polimerica autoprodotta adesa alla superficie mucosa

fppt.com

BIOFILM BATTERICI EXTRACELLULARI

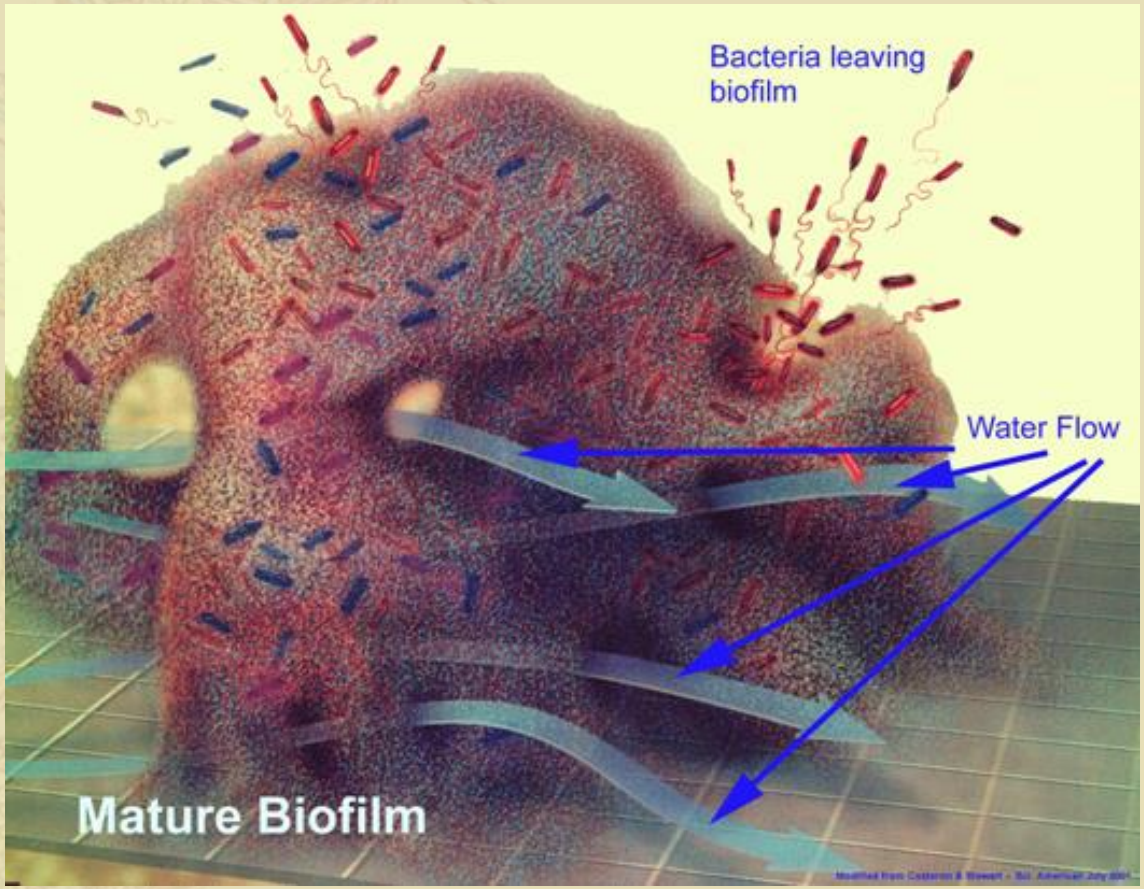

***Persister Cells*: parte più profonda del Bíofilm, (1%) di cellule batteriche quiescenti, che aderiscono alla parete vescicale, penetrando negli spazi intercellulari, ove il coating vescicale e l'integrità della mucosa (tight junctions) sono compromessi. Inaccessibilii agli antibiotici**

fppt.com

INTRACELLULAR BACTERIAL COOMUNITIES

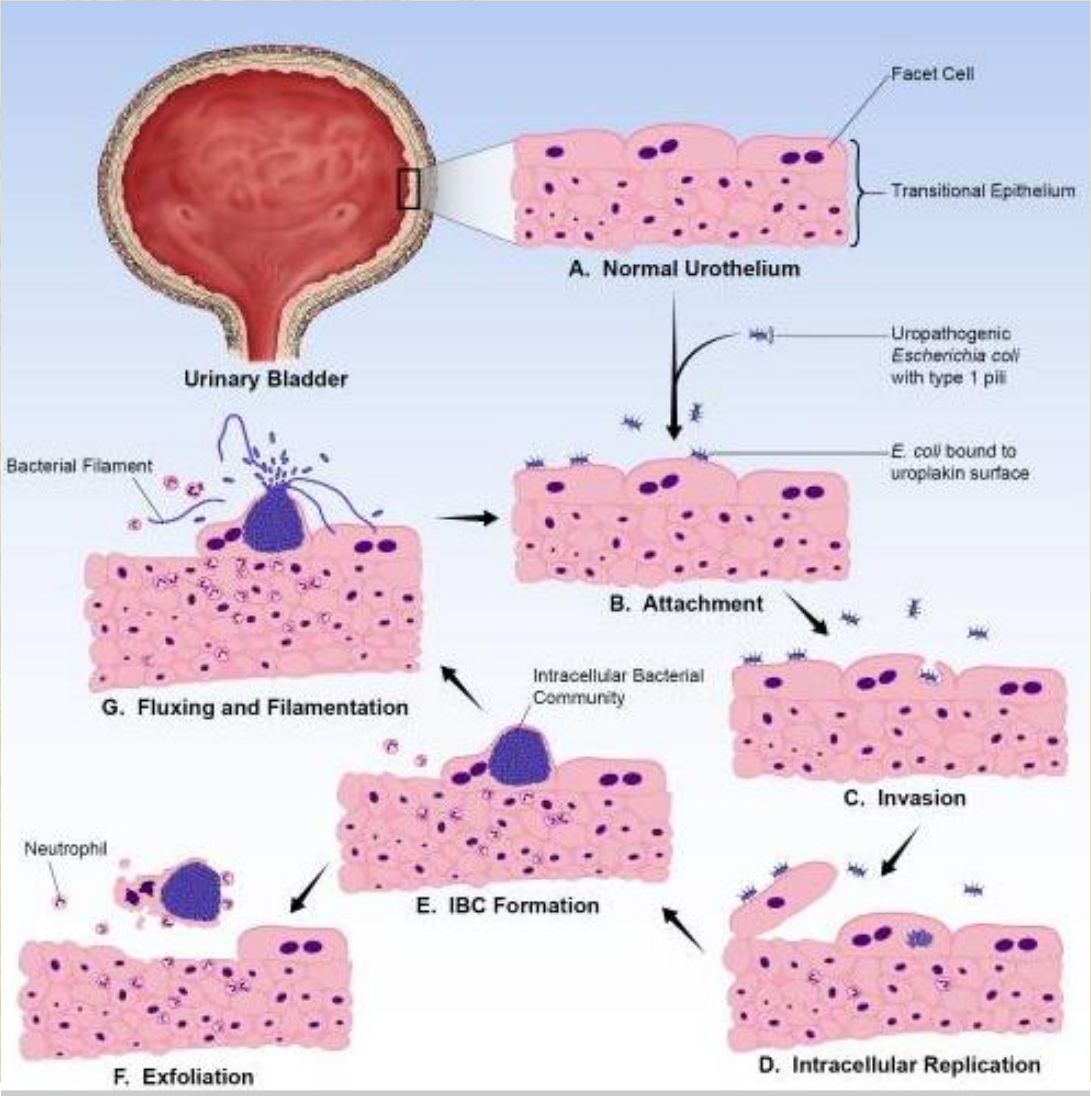

PLoS Med. 2007 Dec;4(12):e329.

Detection of intracellular bacterial communities in human urinary tract infection.

Rosen DA, Hooton TM, Stamm WE, Humphrey PA, Hultgren SJ.

Department of Molecular Microbiology and Microbial Pathogenesis, Washington University School of Medicine, St. Louis, Missouri, United States of America.

pt.com

BPS: BLADDER PAIN SYNDROME
IC: INTERSTITIAL CYSTITIS
Definizione

Persistent or recurrent chronic pelvic pain, pressure or discomfort perceived to be related to the urinary bladder accompanied by at least one other urinary such as increased daytime and night-time frequency, an urgent need to void, in the absence of proven urinary infection and of any identifsymptomiable pathology which could explain these symptoms.

ICS

fppt.com

BPS: *Bladder Pain Syndrome*

Suprapubic pain at bladder filling, accompanied by other symptoms such as increased daytime and nightime frequency

There is an absence of proven urinary infection or other obvious pathology

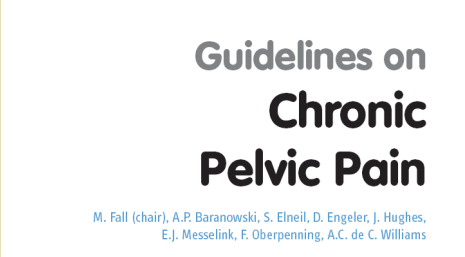

fppt.com

IC: *Interstitial Cystitis*
Cistite Interstiziale
DIAGNOSI

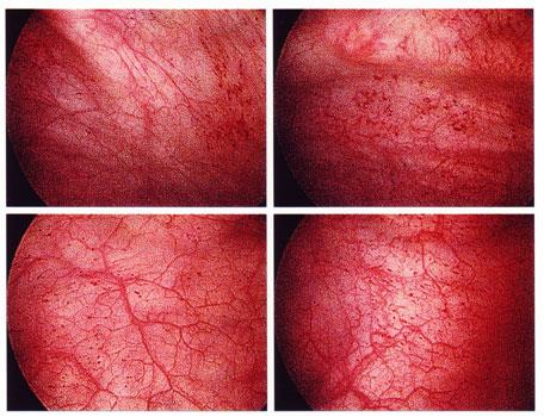

Glomerulations Grade 2

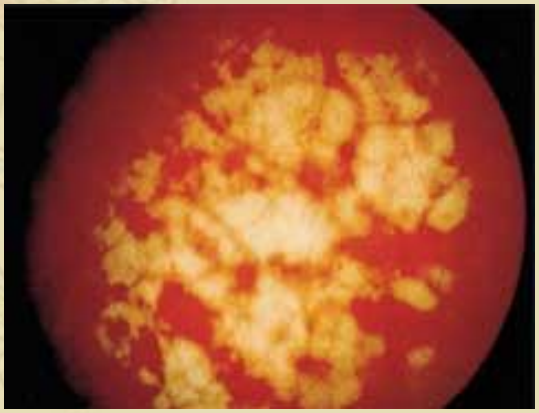

Glomerulations Grade 3

Hunner's Ulcer

[a] **Cystoscopy: glomerulatios grade 2 – 3**

[b] **With or without glomerulations**

[c] **Histology showing inflammatory infiltrates and/or detrusor mastocytosis (mast cell count > 28 mast cells/mm^2) and/or granulation tissue and/or intrafascicular fibrosis**

ESSIC EUROPEAN SOCIETY FOR THE STUDY OF IC/PBS

European Society for the Study of IC/PBS

Bladder Pain Syndrome - Painful Bladder Syndrome - Interstitial Cystitis

fppt.com

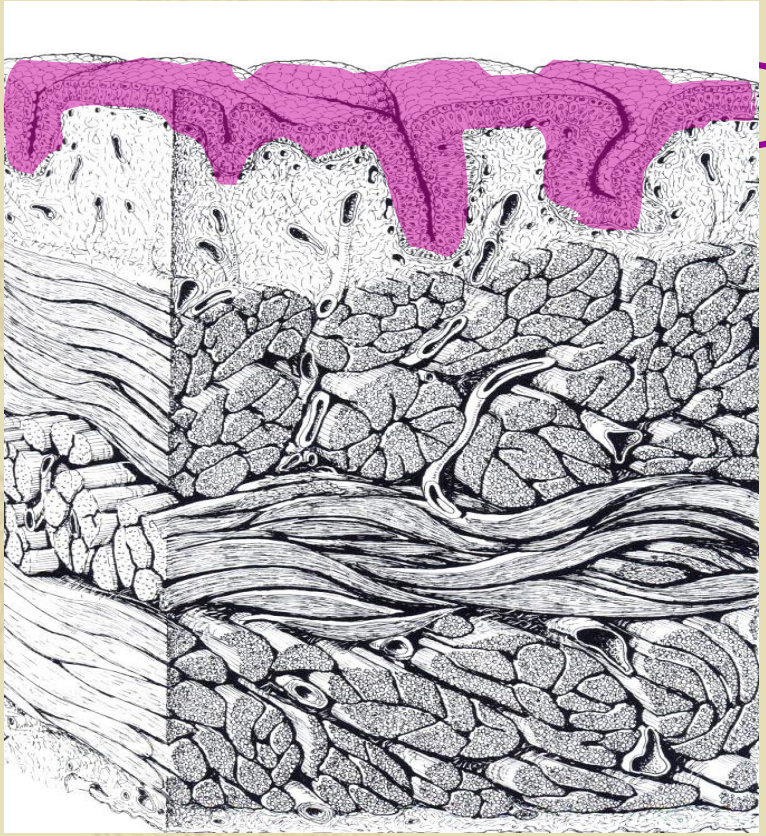

UROTHELIUM

Courtesy of Tajana

fppt.com

Barriera apicale

Barriere laterali

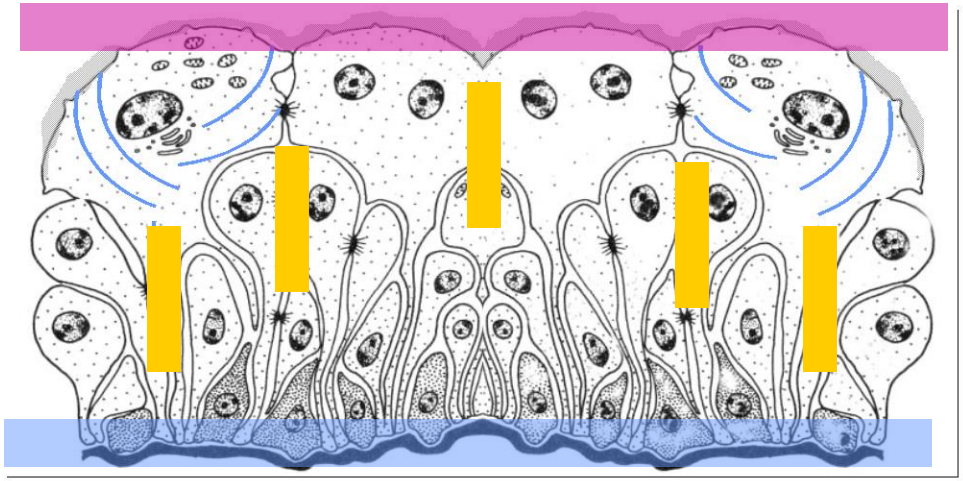

Barriere laterali

Barriera basale

Courtesy of Tajana

Barriera apicale

Il Coating

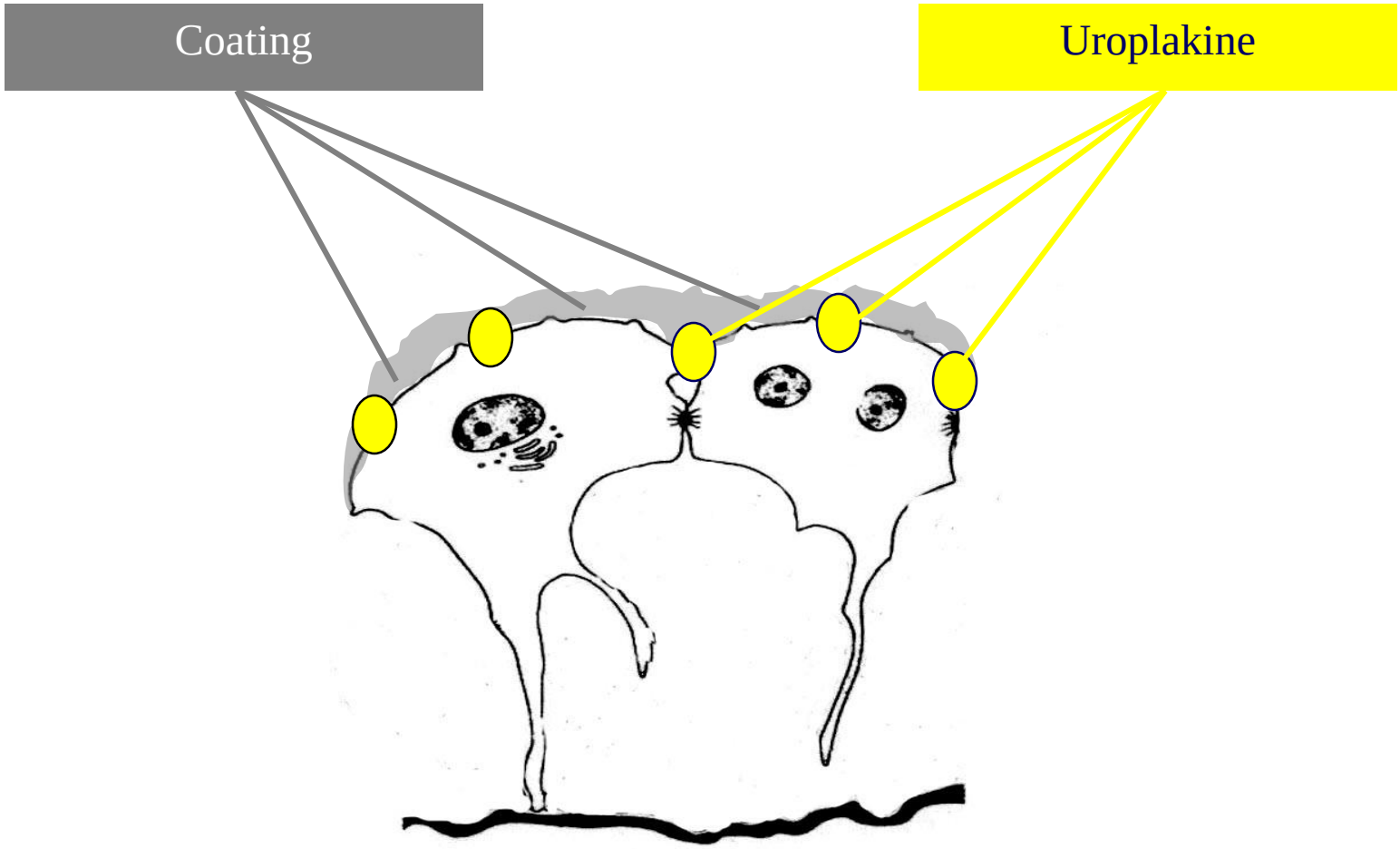

Cellule “ombrello”

Courtesy of Tajana

COATING

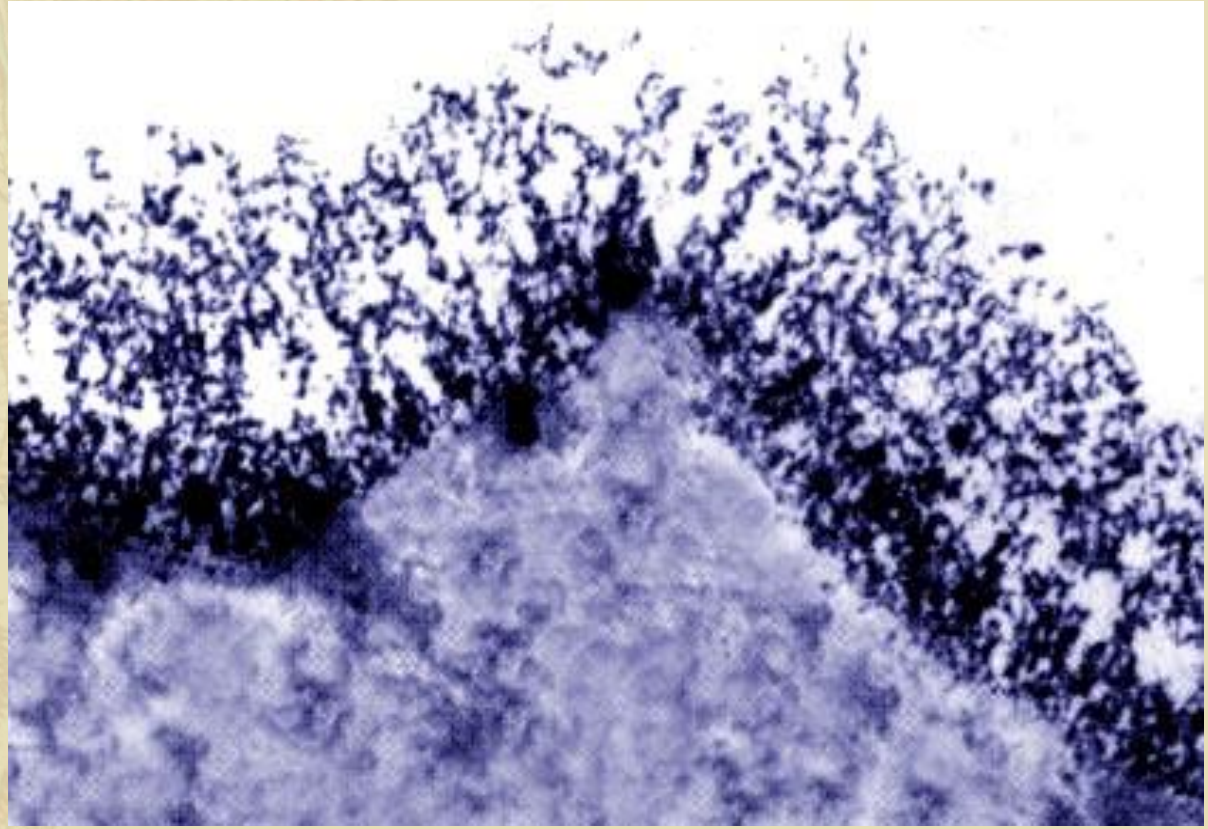

Peixoto EB 2005

Courtesy of Tajana

fppt.com

COATING *in vivo*

Laser Confocal Endomycroscopy
(Sonn GA 2009)

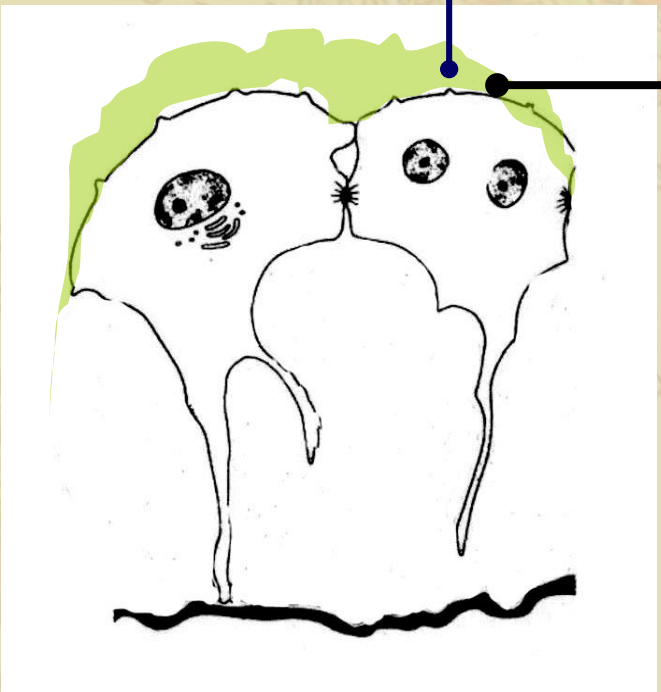

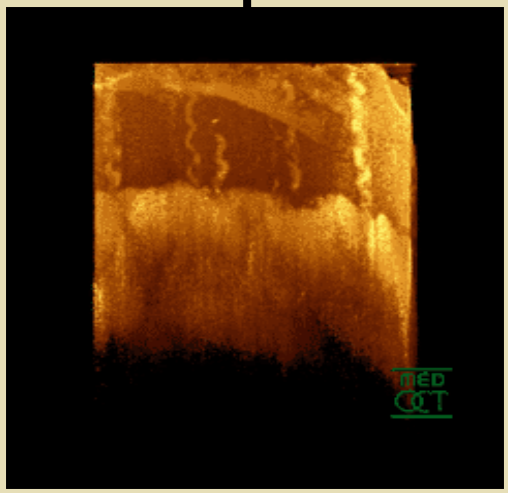

Ultrahigh resolution optical coherence tomography
(Hermes B 2008)

fppt.com

“Attacco al Coating”

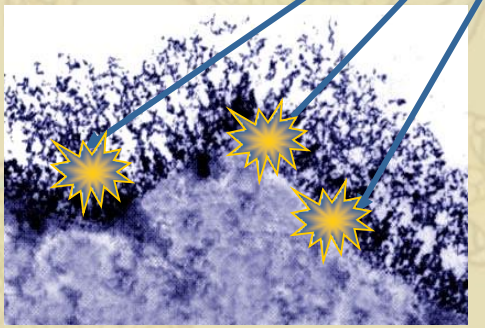

Coating

Peixoto EB 2005

Courtesy of Tajana

fppt.com

“Attacco al Coating”

Scomparsa del Coating

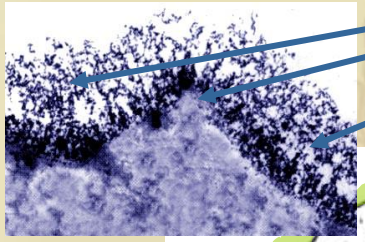

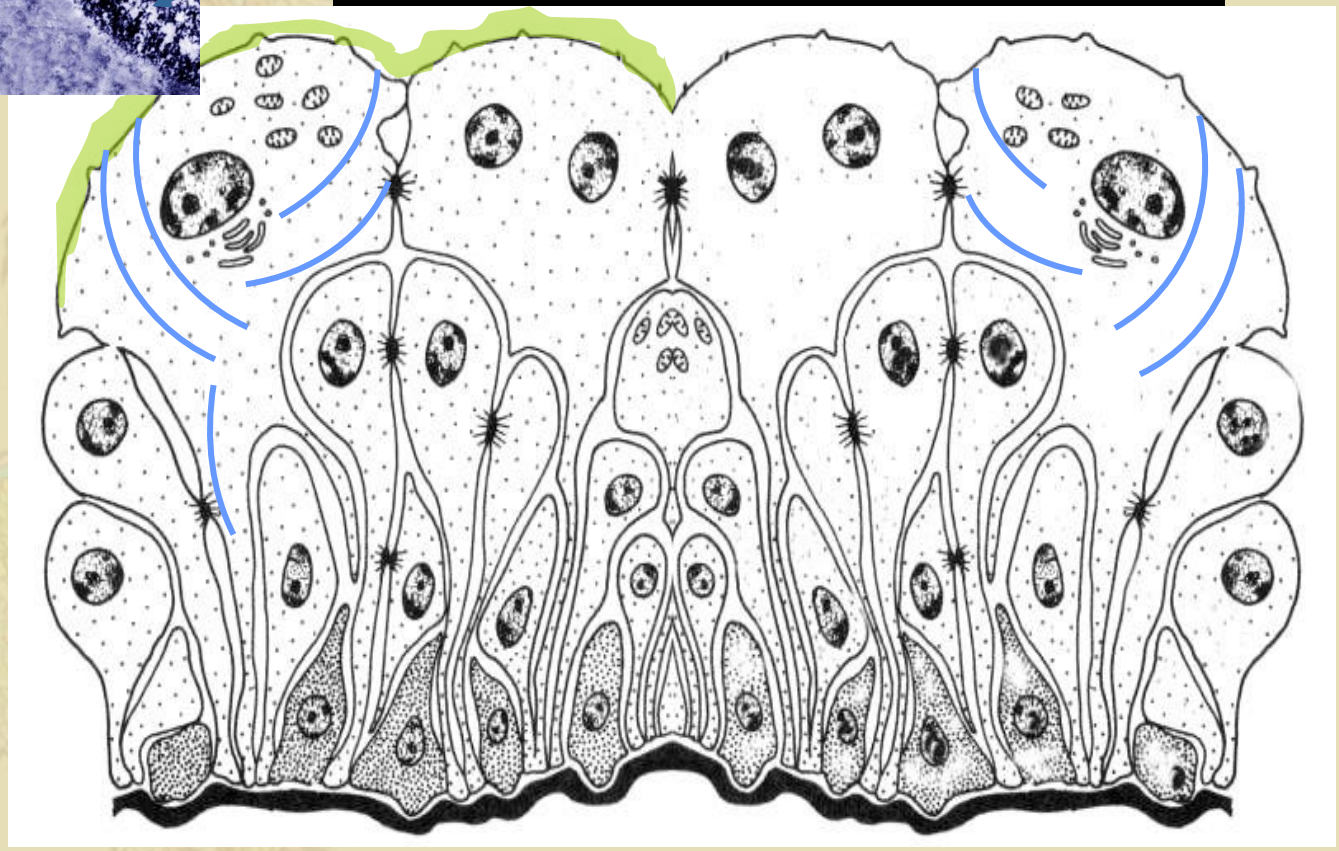

Peixoto EB 2005

Courtesy of Tajana

fppt.com

“Attacco al Coating”

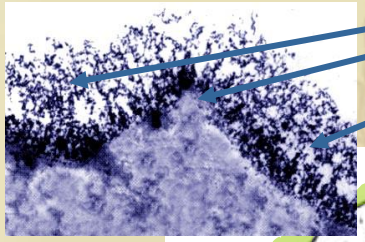

Permeabilità

Scomparsa del Coating

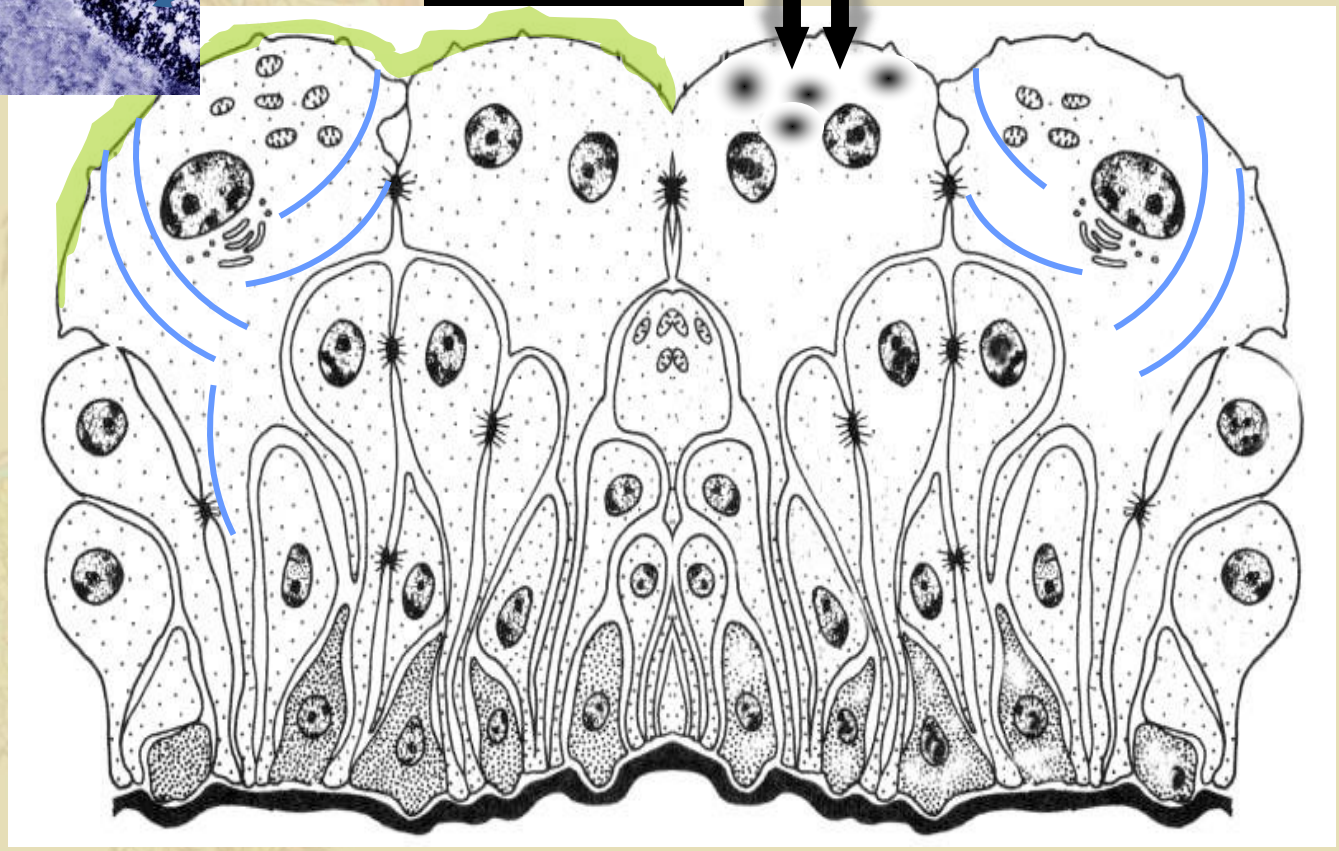

Peixoto EB 2005

Courtesy of Tajana

fppt.com

“cedimento strutturale”

VIOLAZIONE DELLE BARRIERE

BARRIERS BREAKDOWN

Interstizio

Courtesy of Tajana

fppt.com

"**Structural Breaking Down**" of the ***Barriers***

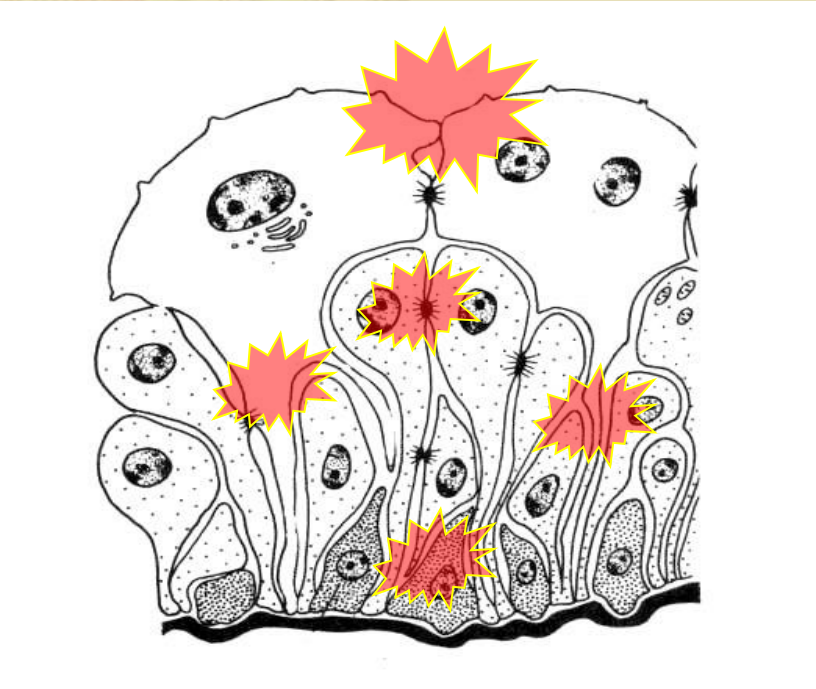

Interstice

Courtesy of Tajana

fppt.com

Percolazione intercellulare

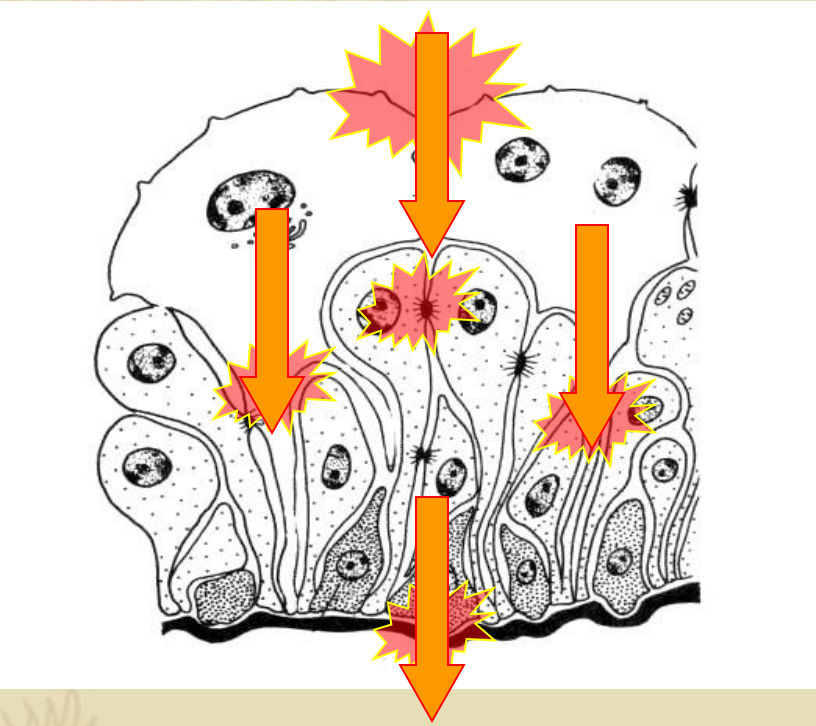

Interstizio

Courtesy of Tajana

fppt.com

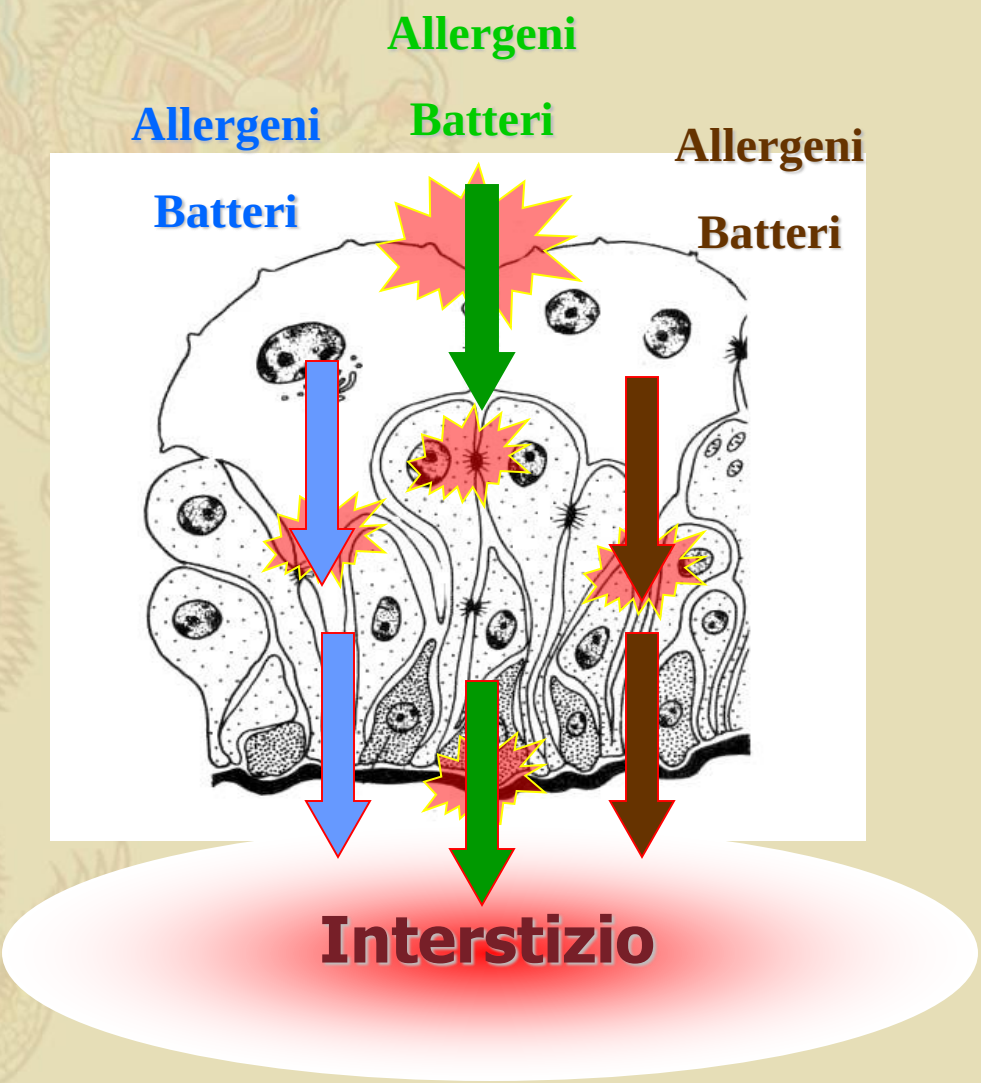
Allergeni
Allergeni
Batteri
Allergeni
Batteri
Batteri
Interstizio

fppt.com

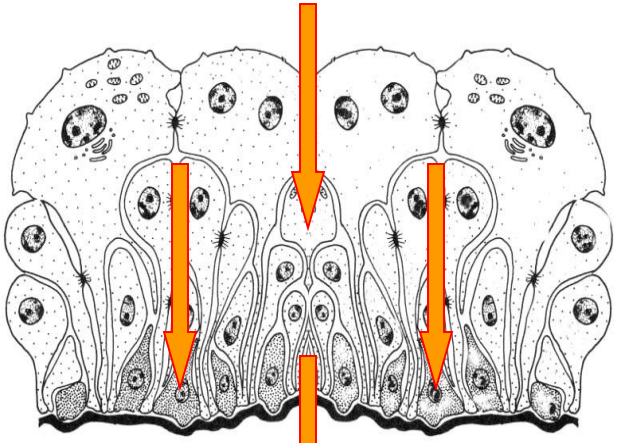

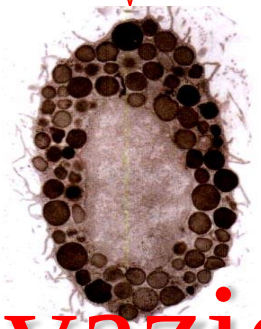

Attivazione MASTOCITA

Courtesy of Tajana

Sindrome del Dolore Vescicale
Bladder Pain Syndrome BPS
Cistite Interstiziale
Interstitial Cystitis - IC

Violazione delle Barriere Uroteliali

Urothelial Barriers Break Down

Urothelium Leakage Syndrome

CASO CLINICO n. 1

fppt.com

Caso Clinico n. 1 – Nadia P. aa 32

Motivo della Consulenza: Bruciore uretrale e vescicale in Paziente con diagnosi di Vulvodinia

Sintomi del Basso Apparato Urinario

(*Lower Urinary Tract Symptoms* LUTS)

RIEMPIMENTO: **bruciore e dolore vescicale che aumenta se trattiene. Bruciore uretrale permanente**. Frequenza minzionale diurna: 60-90 min, notturna 1-3x.

MINZIONE: NON bruciore, anzi temporaneo sollievo. Ripresa del dolore uretrale vescicale al termine della minzione.

2013: 2 episodi di cistiti emorragiche con isolamento di ***Escherichia coli***

2014 – 2019: 16 **urinocolture negative**

Nadia

fppt.com

Caso Clinico n. 1 – Nadia P. aa 32

Vulvodinia: Sente **bruciore vulvare** da seduta, con gli assorbenti, con le gambe accavallate, non riesce ad avere rapporti. Ha fatto TENS e FKT, Lyrica, Laroxyl, ozonoterapia, neuralterapia senza beneficio

Ciclo: 30-32 gg, preceduto da tensione al seno, con sbalzi d'umore, pancia gonfia, poi parte piano il 1° giorno con tanto **mal di pancia e di schiena,** poi più forte il 2° e il 3° giorno, con **sangue scuro e grossi coaguli scuri**, il 4° giorno inizia a ridursi, 5° poche gocce

Addome gonfio, con molta aria. Alterna stipsi a scariche (**IBS**). Digestione lenta. Alimentazione: il vino bianco lo sente immediatamente in vescica, evita il piccante, le bevande gassate

Nadia

fppt.com

Caso Clinico n. 1 – Nadia P. aa 32

Cistoscopia: trabecolature, teleangectasia

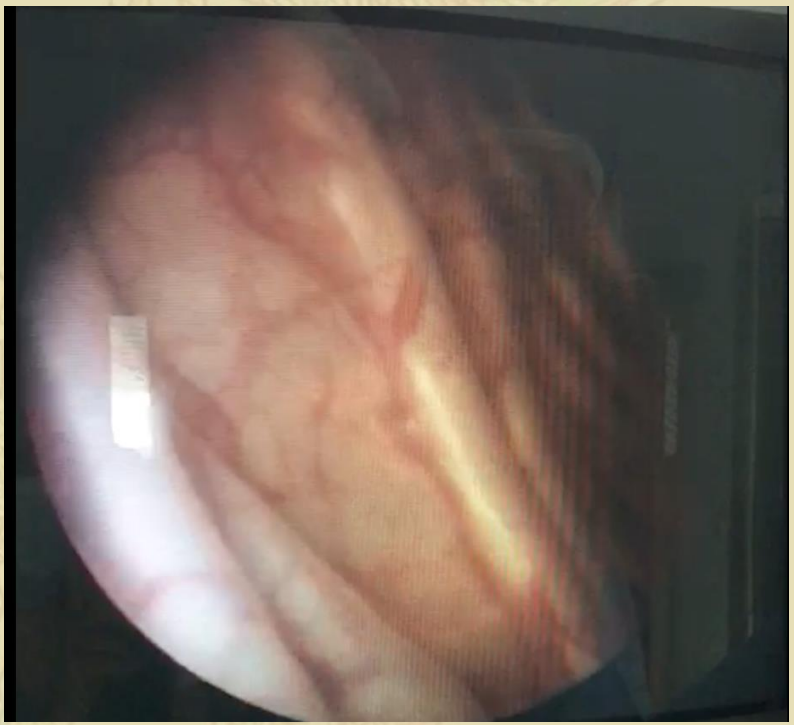

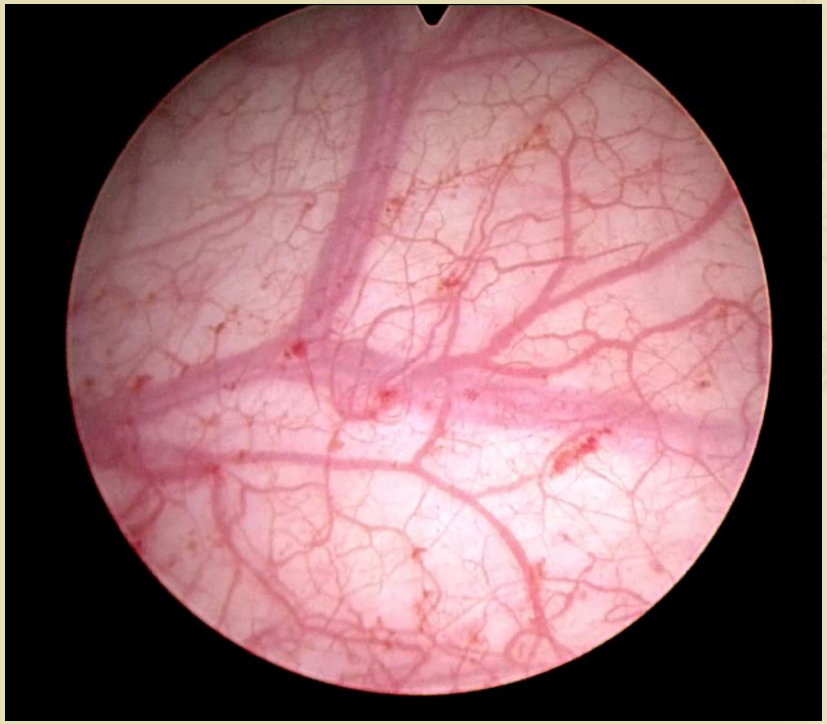

Nadia

fppt.com

Caso Clinico n. 1 – Nadia P. aa 32

Cistoscopia: *glomerulations*

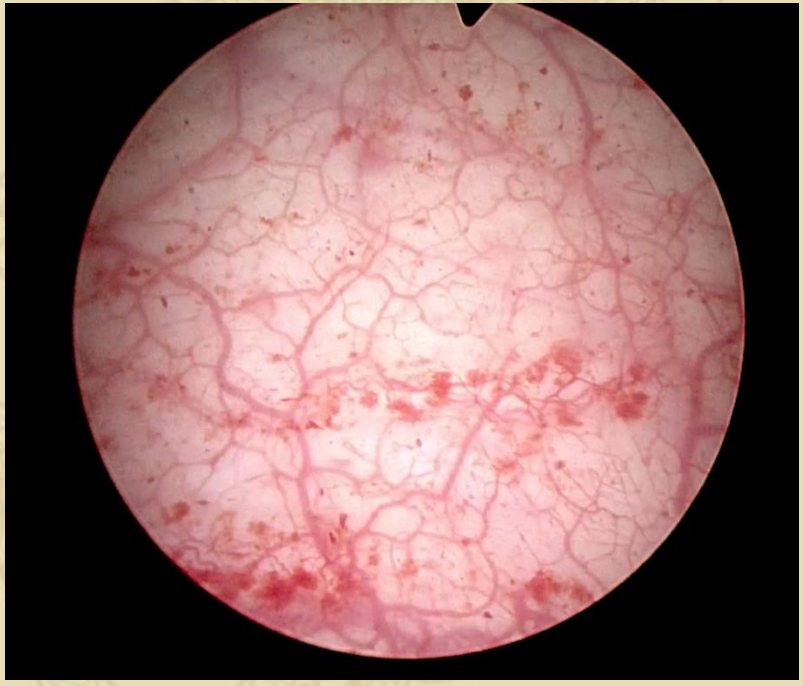

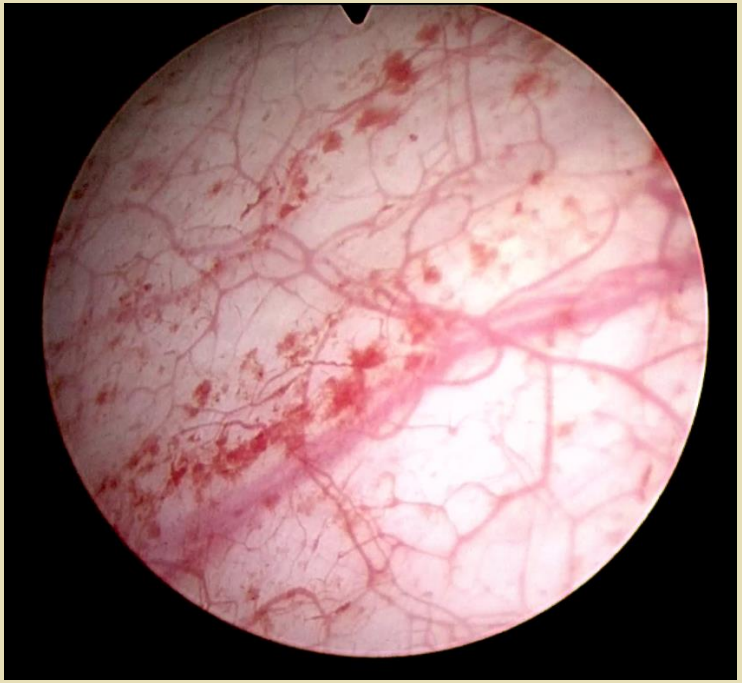

Nadia

fppt.com

Caso Clinico n. 1 – Nadia P. aa 32

ESAME ISTOLOGICO

Mucosa vescicale completamente disepitelizzata e comprendente nel corion **mastociti**, positivi all'analisi immunoistochimica per il marcatore CD117, in numero di **66** per millimetro/quadrato. Urotelio con diffusi aspetti di metaplasia squamosa

Il quadro morfologico ed immunoistochimico sono compatibili con cistite interstiziale.

Nadia

fppt.com

Caso Clinico n. 1 – Nadia P. aa 32

DIAGNOSI

Cistite Interstiziale (*Interstitial Cystitis*) con iniziale fibrosi vescicale

COMORBILITA' ASSOCIATE

Vulvodinia - Vestibulite Vulvare (*Vulvar Vestibulitis*)

Algodismenorrea (*Painful Periods*)

Sindrome dell'intestino irritabile (*Irritable Bowel Syndrome* – IBS)

Nadia

fppt.com

CASO CLINICO n. 2

fppt.com

Caso Clinico n. 2 – Ilaria M. aa 26

Motivo della Consulenza: Cistiti Ricorrenti in Paziente con diagnosi di Vulvodinia

Da Marzo 2013, inizio dei rapporti sessuali con persistente e forte dispareunia (diagnosi di **vestibulite vulvare/vulvodinia**) e contemporanea comparsa di **cistiti ricorrenti post-coitali (*Post Coital Cystitis*),** con insorgenza da 12 a 24 ore dopo il rapporto.

Numerosissime **urinocolture positive per *Escherichia coli.*** Ha assunto numerosissimi antibiotici, con progressiva **antibiotico-resistenza** (ora: betalattamici, cefalosporine, chinolonici, fosfomicina, nitrofurantoina)

Da 3 anni: diagnosi di **Fibromialgia**

Ilaria 1

fppt.com

Caso Clinico n. 2 – Ilaria M. aa 26

Vagina: ricorrenti episodi di bruciore, gonfiore, pprurito, perdite ricottose, interpretate come ***Candida*:** assume fluconazolo

Ano: bruciore e prurito peri-anale

Pancia: crampi, gonfiore e sonnolenza post-prandiale.

Alvo: alterna stipsi e plurime evacuazioni giornaliere di feci non formate (Bristol 5-6): **IBS**

Ilaria 2

fppt.com

Caso Clinico n. 2 – Ilaria M. aa 26

Energia: stanca al mattino, meglio alla sera

Cuore: palpitazioni (cuore in gola)

Bocca: Stomatite Aftosa Ricorrente, con frequenti afte su gengive e sotto-linguali

Gola: sensazione di corpo estraneo bloccato in gola (“nocciolo di prugna”)

Ilaria 3

fppt.com

Caso Clinico n. 2 – Ilaria M. aa 26

Cistoscopia: iperemia, teleangectasie

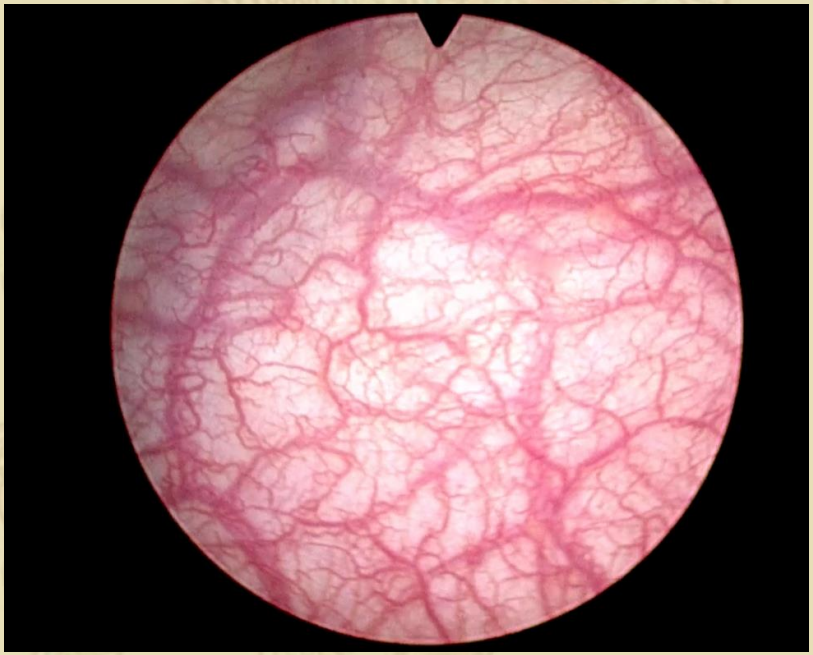

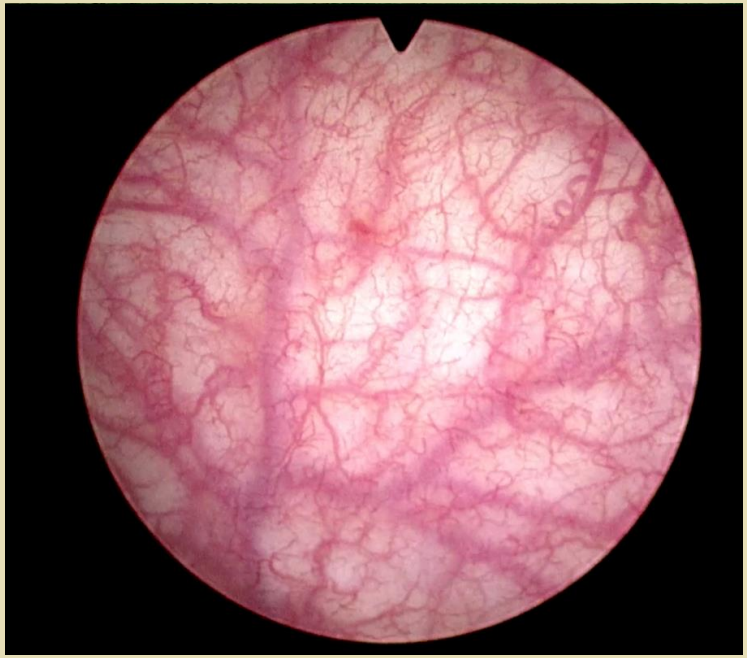

Ilaria

fppt.com

Caso Clinico n. 2 – Ilaria M. aa 26

Cistoscopia: *glomerulations*

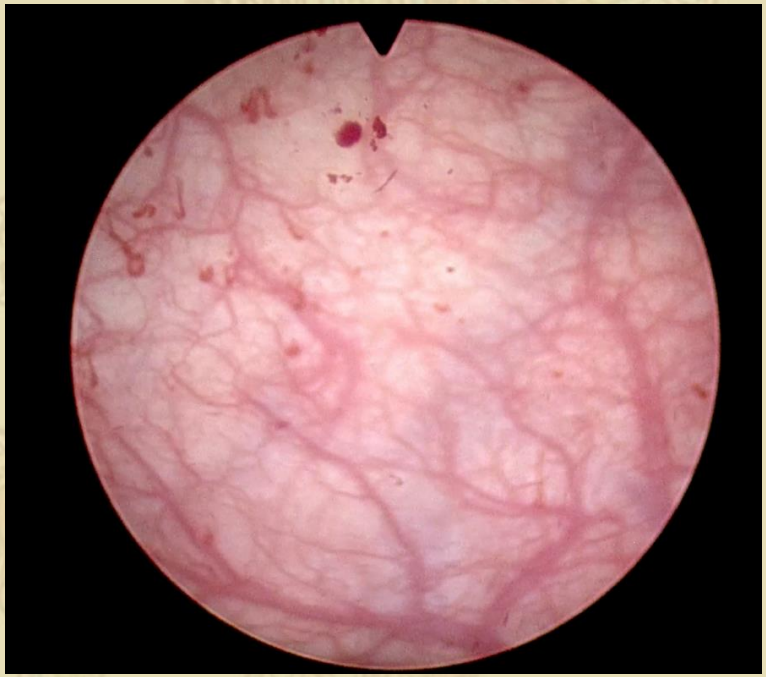

Ilaria

fppt.com

Caso Clinico n. 2 – Ilaria M. aa 26

ESAME ISTOLOGICO

Frustoli di parete vescicale comprendenti urotelio privo di atipie e nel corion **mastociti,** positivi all'analisi immunoistochimica per il marcatore CD117, in numero di **96** per millimetro/quadrato; nella tonaca muscolare non sono presenti mastociti (A)

Il quadro morfologico ed immunoistochimico sono compatibili con cistite interstiziale.

Ilaria

fppt.com

Caso Clinico n. 2 – Ilaria M. aa 26

DIAGNOSI

Cistite Interstiziale (*Interstitial Cystitis*) in Paziente con Cistiti Ricorrenti (Recurrent Urinary Tract Infections - RUTI's)

COMORBILITA' ASSOCIATE

Vaginiti ricorrenti micotiche da *Candida spp*

Vulvodinia - Vestibulite Vulvare (*Vulvar Vestibulitis)*

Sindrome dell'intestino irritabile (*Irritable Bowel Syndrome* – IBS)

Fibromialgia (*Fibromyalgia*)

Stomatite Aftosa Ricorrente (SAR)

Ilaria

fppt.com

Colpo di scena

RUTI's e IC imparentate?

RUTI's e IC figlie della
Leaky Bladder Syndrome

fppt.com

violazione delle barriera vescicale
attivazione dell’interstizio

RUTI’S BPS - IC

fppt.com

Recurrent Urinary Tract Infections RUTI's

PLoS Pathog. 2010 August; 6(8): e1001042. PMCID: PMC2930321
Published online 2010 August 12. doi: 10.1371/journal.ppat.1001042.

Copyright Hannan et al. This is an open-access article distributed under the terms of the Creative Commons Attribution License, which permits unrestricted use, distribution, and reproduction in any medium, provided the original author and source are credited.

Early Severe Inflammatory Responses to Uropathogenic *E. coli* Predispose to Chronic and Recurrent Urinary Tract Infection

Thomas J. Hannan,[1,2] Indira U. Mysorekar,[2,3] Chia S. Hung,[1] Megan L. Isaacson-Schmid,[3] and Scott J. Hultgren[1*]

[1]Department of Molecular Microbiology and Center for Women's Infectious Disease Research, Washington University School of Medicine, St. Louis, Missouri, United States of America
[2]Department of Pathology and Immunology, Washington University School of Medicine, St. Louis, Missouri, United States of America
[3]Department of Obstetrics and Gynecology, Washington University School of Medicine, St. Louis, Missouri, United States of America
Craig R. Roy, *Editor*
Yale University School of Medicine, United States of America
* E-mail: hultgren@borcim.wustl.edu

Conceived and designed the experiments: TJH IUM SJH. Performed the experiments: TJH IUM CSH MLIS. Analyzed the data: TJH SJH. Wrote the paper: TJH SJH.

Received October 27, 2009; Accepted July 13, 2010.

fppt.com

NCBI Resources How To

PubMed.gov
US National Library of Medicine
National Institutes of Health

PubMed

Limits Advanced

Display Settings: Abstract

Send to:

FEMS Microbiol Rev. 2012 Mar 9. doi: 10.1111/j.1574-6976.2012.00339.x. [Epub ahead of print]

Host-Pathogen Checkpoints and Population Bottlenecks in Persistent and Intracellular Uropathogenic E. coli Bladder Infection.

Hannan TJ, Totsika M, Mansfield KJ, Moore KH, Schembri MA, Hultgren SJ.

Department of Pathology & Immunology, Washington University School of Medicine, St. Louis, MO, USA.

Abstract

Bladder infections affect millions of people yearly, and recurrent symptomatic infections (cystitis) are very common. The rapid increase in infections caused by multi-drug resistant uropathogens threatens to make recurrent cystitis an increasingly troubling public health concern. Uropathogenic E. coli (UPEC) cause the vast majority of bladder infections. Upon entry into the lower urinary tract, UPEC face obstacles to colonization that constitute population bottlenecks, reducing diversity and selecting for fit clones. A critical mucosal barrier to bladder infection is the epithelium (urothelium). UPEC bypass this barrier when they invade urothelial cells and form intracellular bacterial communities (IBCs), a process which requires type 1 pili. IBCs are transient in nature, occurring primarily during acute infection. Chronic bladder infection is common and can be either latent, in the form of the Quiescent Intracellular Reservoir (QIR), or active, in the form of asymptomatic bacteriuria (ASB/ABU) or chronic cystitis. In mice, the fate of bladder infection: QIR, ASB, or chronic cystitis, is determined within the first 24 hours of infection and constitutes a putative host-pathogen mucosal checkpoint that contributes to susceptibility to recurrent cystitis. Knowledge of these checkpoints and bottlenecks is critical for our understanding of bladder infection and efforts to devise novel therapeutic strategies. © 2012 Federation of European Microbiological Societies. Published by Blackwell Publishing Ltd. All rights reserved.

© 2012 Federation of European Microbiological Societies. Published by Blackwell Publishing Ltd. All rights reserved.

fppt.com

BLADDER MICROBIOMA

Nat Commun. 2018 Apr 19;9(1):1557. doi: 10.1038/s41467-018-03968-5.

Culturing of female bladder bacteria reveals an interconnected urogenital microbiota.

Thomas-White K[1], Forster SC[2,3,4], Kumar N[2], Van Kuiken M[5], Putonti C[6,7,8], Stares MD[2], Hilt EE[1], Price TK[1], Wolfe AJ[9], Lawley TD[10].

Whole-genome analysis of bacterial strains isolated from the vagina and bladder in the same women identifies highly similar *Escherichia coli, Streptococcus, Lactobacillus iners, and Lactobacillus crispatus*

fppt.com

BLADDER MICROBIOMA

Nat Commun. 2018 Apr 19;9(1):1557. doi: 10.1038/s41467-018-03968-5.

Culturing of female bladder bacteria reveals an interconnected urogenital microbiota.

Thomas-White K[1], Forster SC[2,3,4], Kumar N[2], Van Kuiken M[5], Putonti C[6,7,8], Stares MD[2], Hilt EE[1], Price TK[1], Wolfe AJ[9], Lawley TD[10].

suggesting an interlinked

female urogenital microbiota

that is not only limited to pathogens

but is also characteristic of

health-associated commensals.

fppt.com

RUTI's OAB BPS/IC

CONTINUOUS PROCESS

With barrier breakdown

fppt.com

J Clin Microbiol. 2014 Mar;52(3):871-6. doi: 10.1128/JCM.02876-13. Epub 2013 Dec 26.

Urine is not sterile: use of enhanced urine culture techniques to detect resident bacterial flora in the adult female bladder.

Hilt EE[1], McKinley K, Pearce MM, Rosenfeld AB, Zilliox MJ, Mueller ER, Brubaker L, Gai X, Wolfe AJ, Schreckenberger PC.

Author information

1 Infectious Disease and Immunology Institute, Stritch School of Medicine Loyola University Chicago, Maywood, Illinois, USA.

Curr Urol Rep. 2018 Sep 13;19(11):94. doi: 10.1007/s11934-018-0839-3.

Recurrent Urinary Tract Infections in Females and the Overlap with Overactive Bladder.

Nik-Ahd F[1], Lenore Ackerman A[2], Anger J[3].

Author information

1 David Geffen School of Medicine at UCLA, Los Angeles, CA, USA.
2 Division of Urology, Cedars-Sinai Medical Center, Los Angeles, CA, USA.
3 Division of Urology, Cedars-Sinai Medical Center, Los Angeles, CA, USA. Jennifer.Anger@cshs.org.

fppt.com

Front Cell Infect Microbiol. 2019 May 1;9:133. doi: 10.3389/fcimb.2019.00133. eCollection 2019.

The Current Evidence on the Association Between the Urinary Microbiome and Urinary Incontinence in Women.

Govender Y[1], Gabriel I[2], Minassian V[2], Fichorova R[1].

Author information

1 Department of Obstetrics, Gynecology and Reproductive Biology, Harvard Medical School, Brigham and Women's Hospital, Boston, MA, United States.

2 Division of Urogynecology, Brigham and Women's Hospital, Boston, MA, United States.

Front Cell Infect Microbiol. 2019 Apr 8;9:92. doi: 10.3389/fcimb.2019.00092. eCollection 2019.

The Vaginal and Urinary Microbiomes in Premenopausal Women With Interstitial Cystitis/Bladder Pain Syndrome as Compared to Unaffected Controls: A Pilot Cross-Sectional Study.

Meriwether KV[1], Lei Z[1], Singh R[2], Gaskins J[3], Hobson DTG[1], Jala V[2].

Author information

1 Department of Obstetrics and Gynecology, University of Louisville, Louisville, KY, United States.

2 Department of Microbiology and Immunology, James Graham Brown Cancer Center, University of Louisville, Louisville, KY, United States.

3 Department of Bioinformatics and Biostatistics, University of Louisville, Louisville, KY, United States.

fppt.com

J Clin Microbiol. 2019 Oct 16. pii: JCM.00204-19. doi: 10.1128/JCM.00204-19. [Epub ahead of print]

The Utility of DNA Next Generation Sequencing and Expanded Quantitative Urine Culture in the Diagnosis and Management of Chronic or Persistent Lower Urinary Tract Symptoms.

Gasiorek M[1], Hsieh MH[2], Forster CS[3].

Author information

1 University of Texas Health Science Center, San Antonio, TX.
2 Division of Urology, Children's National Health System, Washington, DC.
3 Department of Pediatrics, Children's National Health System, Washington, DC csforster@childrensnational.org.

Abstract

Many patients suffer from chronic, irritative lower urinary tract symptoms (LUTS). The evaluation and management of these patients has proven difficult with the use of standard diagnostic tools, including urinalysis and urine culture. The growing body of literature on the urinary microbiome has looked at the possible implications of the bladder microbiome and dysbiosis, or perturbations in the microbiome, in conditions associated with chronic LUTS. Disorders such as recurrent urinary tract infections (UTI) and interstitial cystitis have been studied utilizing 16S ribosomal RNA rapid next-generation gene sequencing (NGS) and expanded quantitative urine culture (EQUC). In this paper, we first present a brief review of the literature describing the current understanding of the urinary microbiome, and the features and applications of NGS and EQUC. Next, we discuss the conditions most commonly associated with chronic, persistent LUTS, and present the limitations of current diagnostic practices utilized in this patient population. We then review the limited data available surrounding treatment efficacy and clinical outcomes in patients who have been managed based on results provided by these two recently established diagnostic tools (DNA NGS and/or EQUC). Finally, we propose a variety of clinical scenarios in which the use of these two techniques may affect patients' clinical outcomes.

J Urol. 2019 Nov 13:10109701JU000061491286465ab. doi: 10.1097/01.JU.0000614912.86465.ab. [Epub ahead of print]

Re: A Culture-Independent Analysis of the Microbiota of Female Interstitial Cystitis/Bladder Pain Syndrome Participants in the MAPP Research Network.

Wein AJ.

PMID: 31721675 DOI: 10.1097/01.JU.0000614912.86465.ab

fppt.com

INTESTINO VIOLAZIONE DELLA BARRIERA

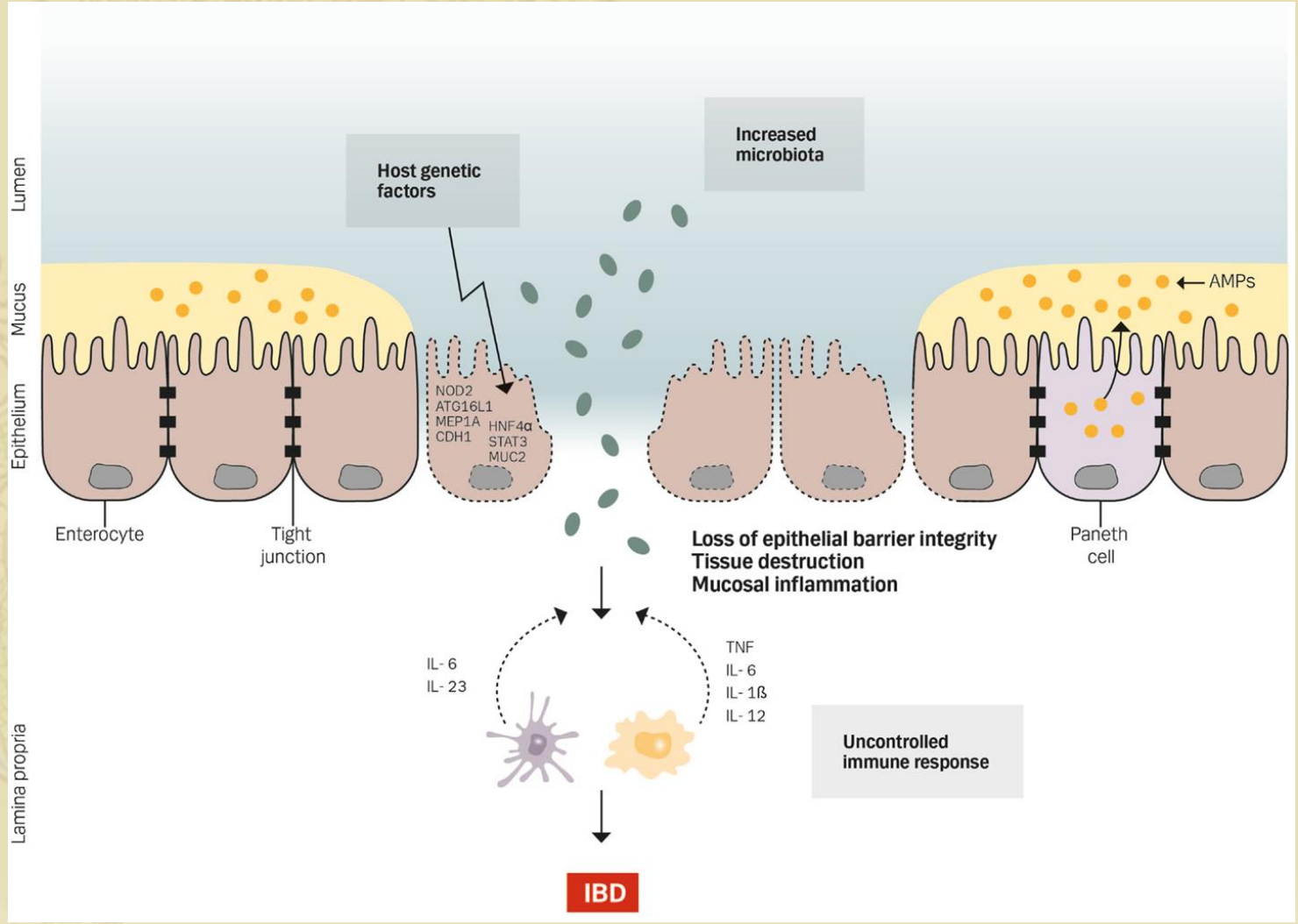

fppt.com

INTESTINO VIOLAZIONE DELLA BARRIERA ATTIVAZIONE DELL'INTERSTIZIO

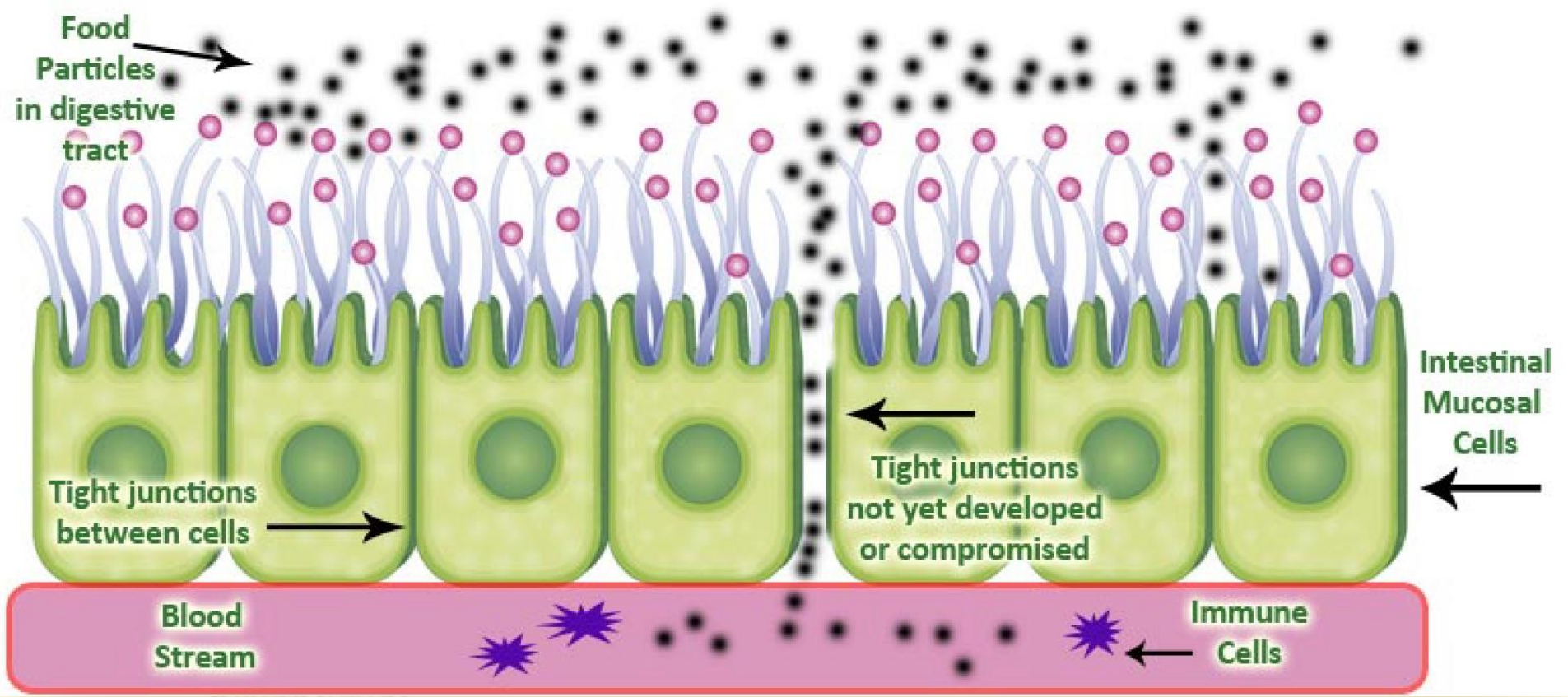

fppt.com

VESCICA VIOLAZIONE DELLA BARRIERA

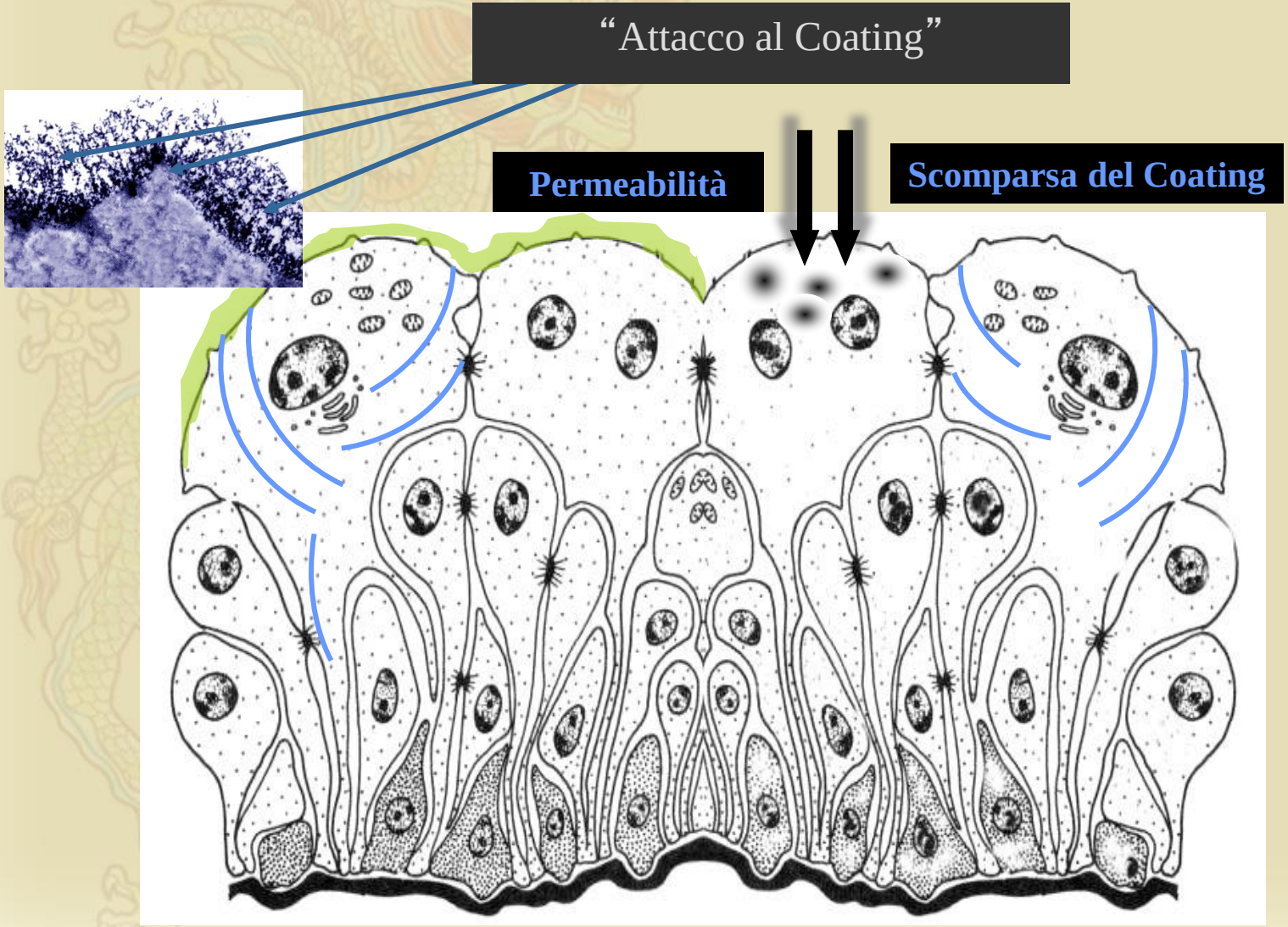

fppt.com

VESCICA VIOLAZIONE DELLA BARRIERA ATTIVAZIONE DELL'INTERSTIZIO

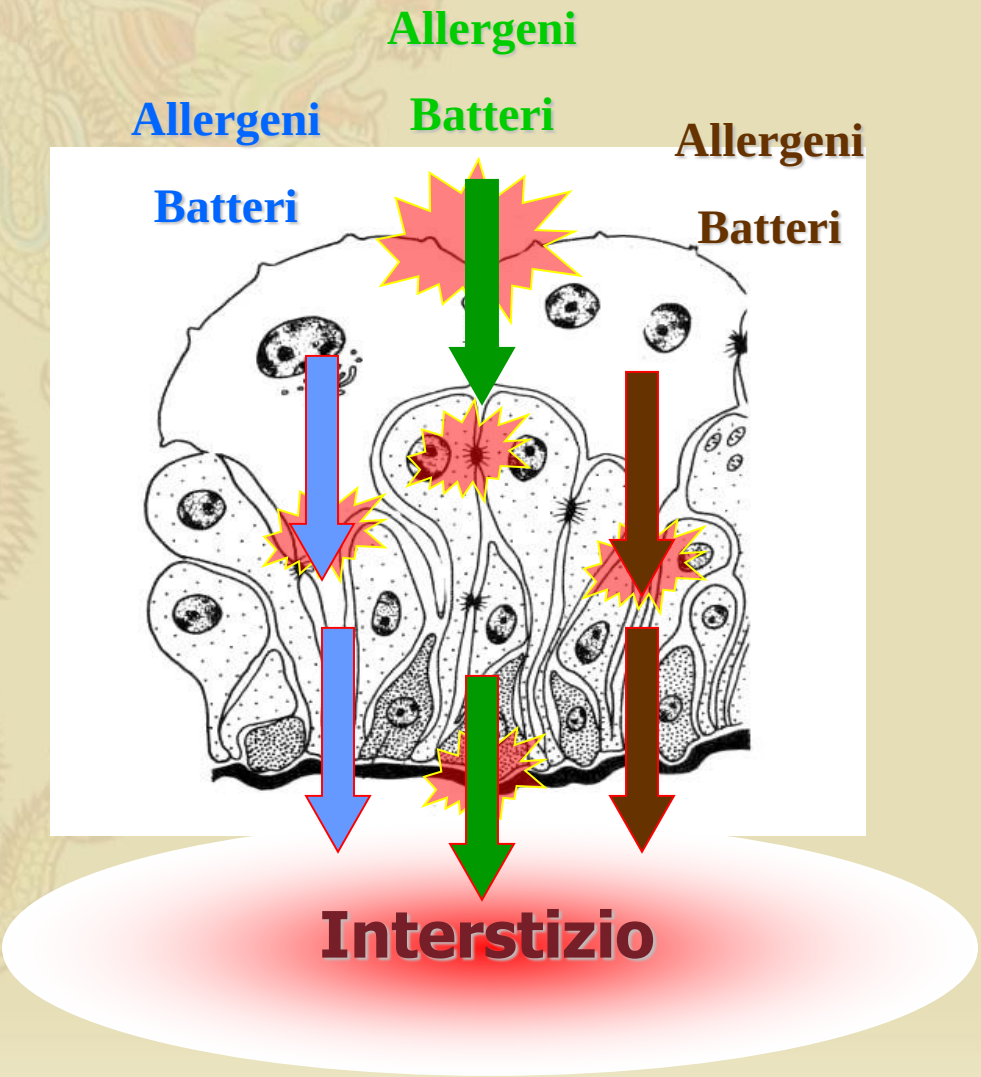

fppt.com

VAGINA VIOLAZIONE DELLA BARRIERA

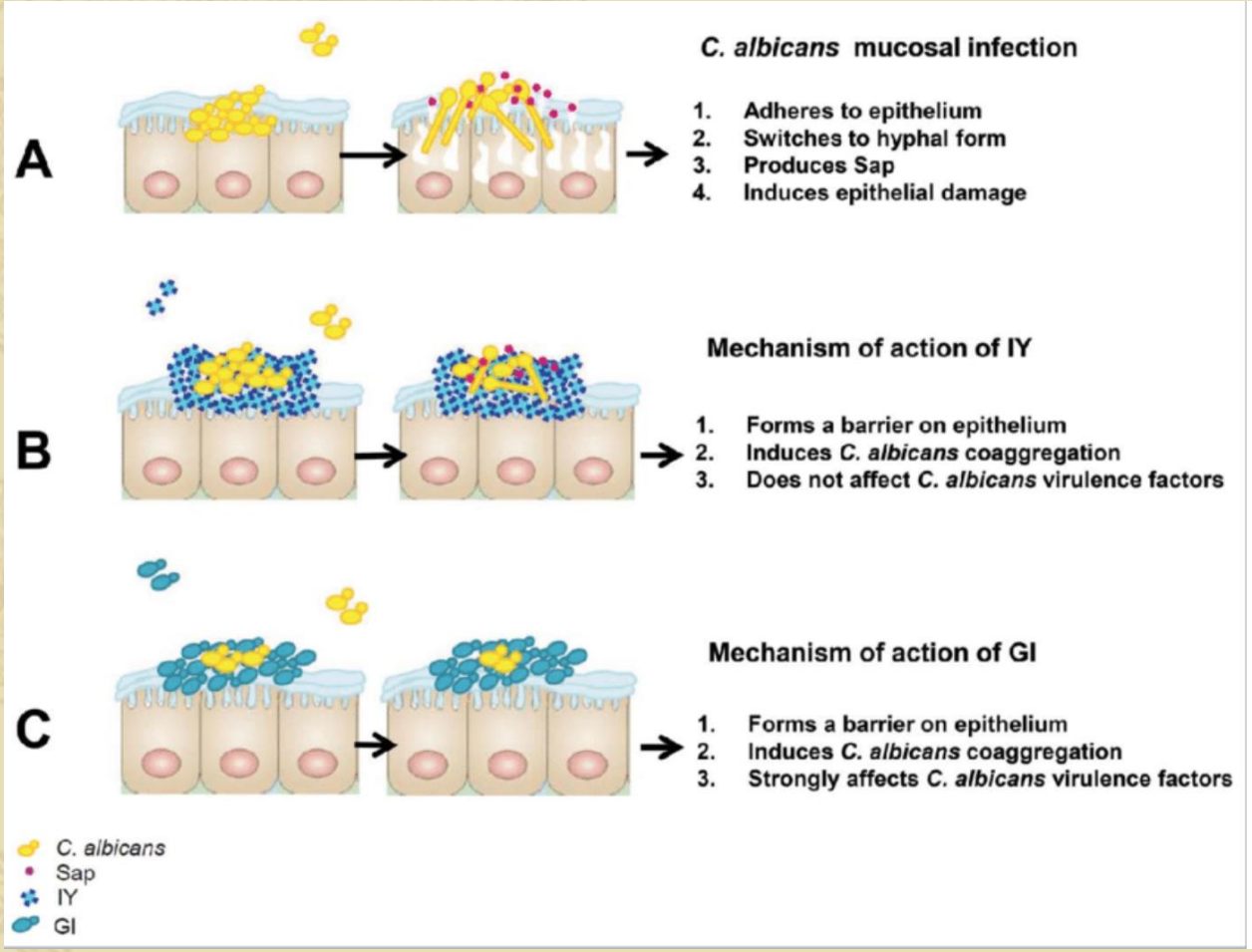

Saccharomyces cerevisiae live yeast (GI)
inactivated whole yeast *Saccharomyces cerevisiae* (IY)

fppt.com

Cellule del Microbiota Umano

Cellule Umane

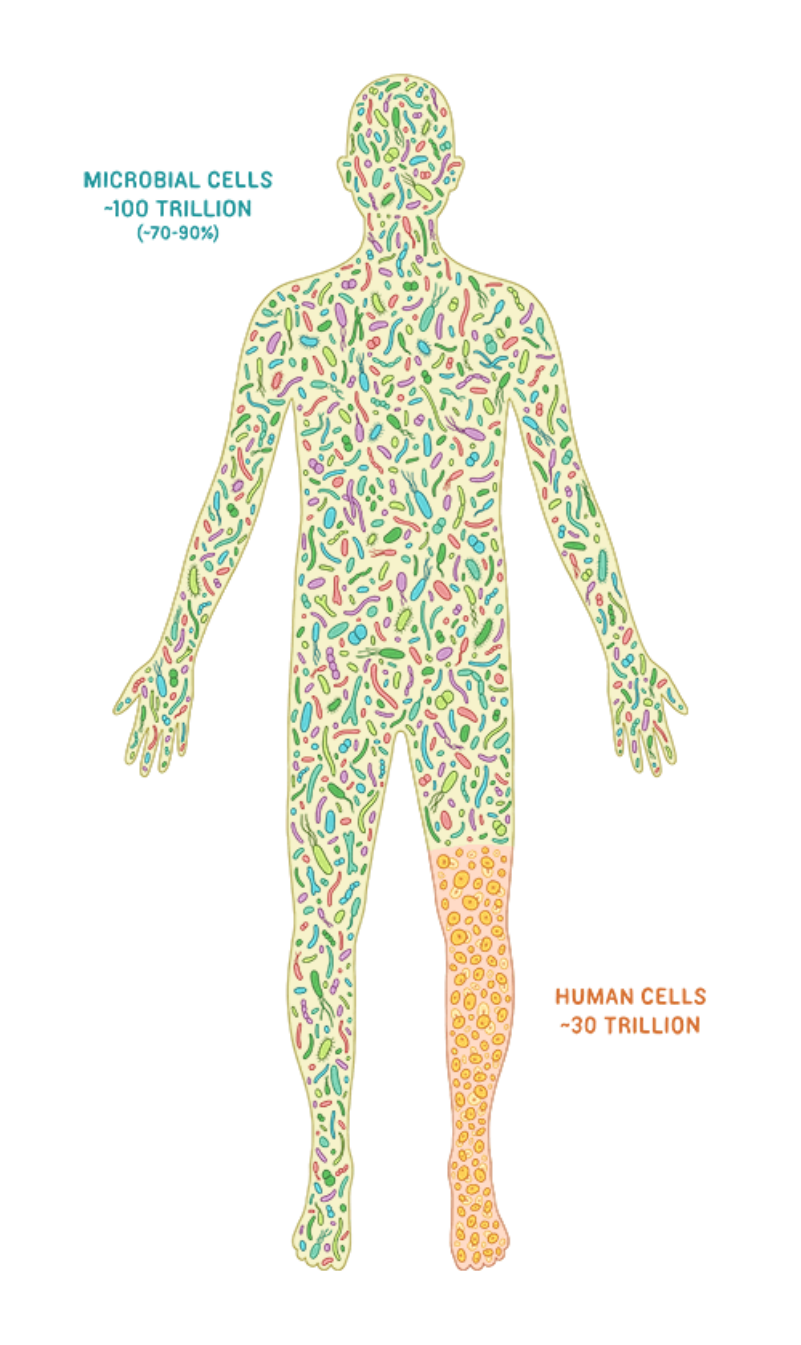

fppt.com

Human Genoma

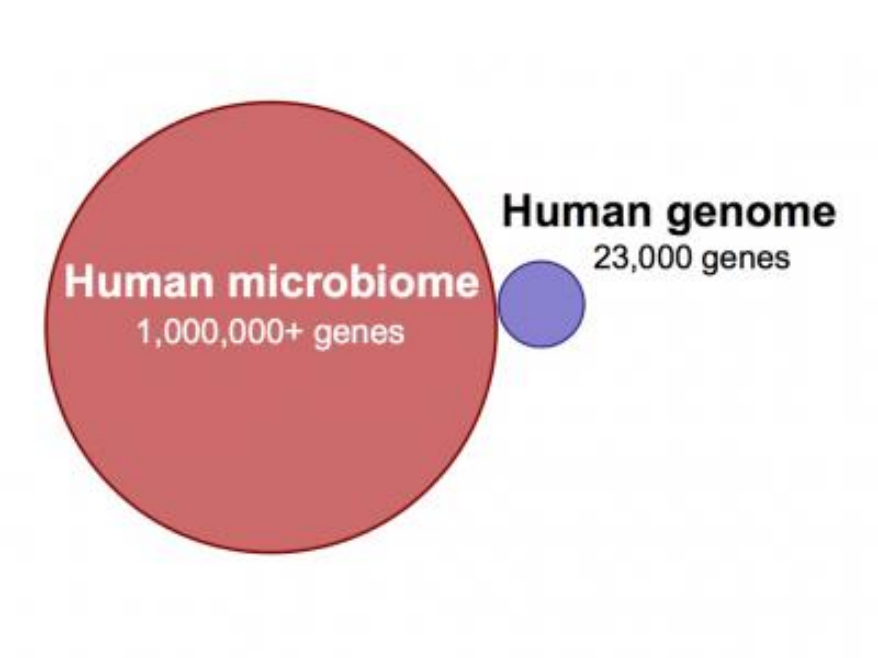

Human
Bacterial
Fungal
Viral
Parasitic
Microbioma

fppt.com

Leaky Barriers Syndrome
Sindrome delle barriere violate

Leaky Gut
Leaky Bladder
Leaky Vagina
Leaky Brain

fppt.com

GRAZIE DELLA

VOSTRA PREZIOSA ATTENZIONE

fppt.com